

\*\*\*

\*

\*\*

\*

\*  
\*\*  
\*\*\*

// :  
// :

/ :

)

( )

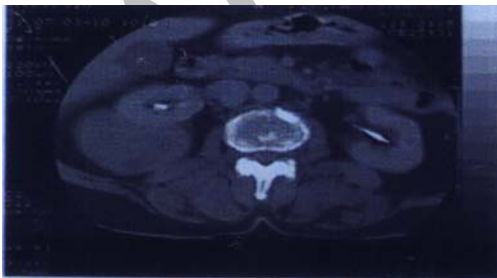
CT Scan × mm

( ) (% /

( )

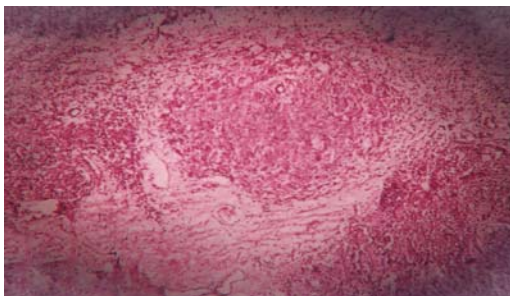
( )

( )



(well defined)

//



---

CT .( )

(Well-demarcated)

.( )

.( )

.( )

1. Maeshima S, Nakamura H, Nishikawa M, et al. Retroperitoneal Schwannomas Simulating Adrenal Tumors. Clin Imaging 1992; 16:121-2.

2. Rodriguez DD, Edreira R A , Garcia MB ,et al. Retroperitoneal Benign Schwannomas, Report of a New Case . Actase Urol Esp 2000; 24(8):685-8.

3. Perhoniemi V, Anttinen I, Kadri F, Saaroi I. Benign Retroperitoneal Schwannomas Scand J Urol Nephrol 1992; 26:85-7.

4. Kuo CH, changchien CS. Sonographic Features of Retroperitoneal Neurilemmoma J clin Ultrasound 1993; 21:309-12.

5. Kim Sh, chio BI. Retroperitoneal Neurilemmoma CT and MRI Finding. AJR 1992; 159: 1023-6.

6. Ben Moualli S, Ben Amma M, et al. Retroperitoneal Schwannoma. Case Report Ann urol (Paris) 2001; 35(5): 2700-2.

**Key words:** Neurilemmoma/ Retroperitoneal/ Neoplasms