



( )

( )

%

( )

(% / ) %

(% ) % /

.(% / )

%

/ ± /

%

:

:

Archives

( )

( )

(.) 1

(.)

Hartman

(.)

(% / )

% /

% /

%

% /

± /

( )

%

( )

( )

/		
/		( )
/		
/		
/		
/		
/		( )

( )

(EUB)

(% )

(% )

(% / )

(% )

(% / )

( )

(% )

(% )

/

( ) / ± /

( )

( )

/	/	/			/	/		

( )	-
-----	---

/		
/		

%

% -

:

(.)

(% )

(% /)

(% /)

/

(. ( )

(.)

(.)

(.)

%

% /

%

% /

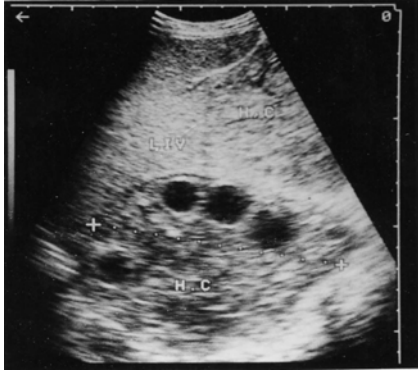% /

(.)

/		
/		
/		
/		
/		
/		

( ) ( )  
% /  
( ) . %

%  
3  
% -



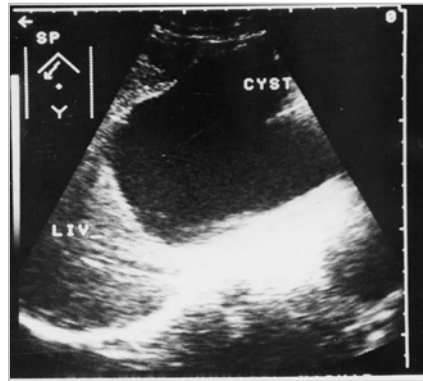
(.)

Archive of SID

(.) % /

( )

6



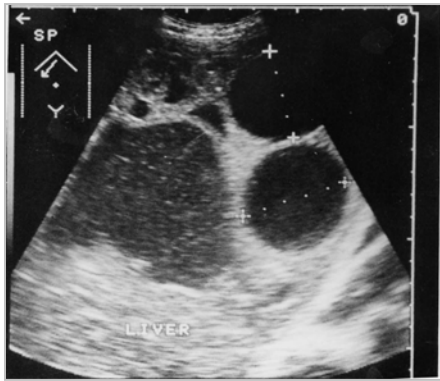
)( )

(

( )

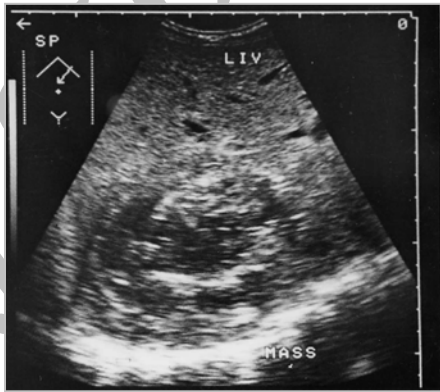water lily sign  
Double line  
shell-like  
Honeycomb

Guerran  
Buligyslu



( )

( ) ( )



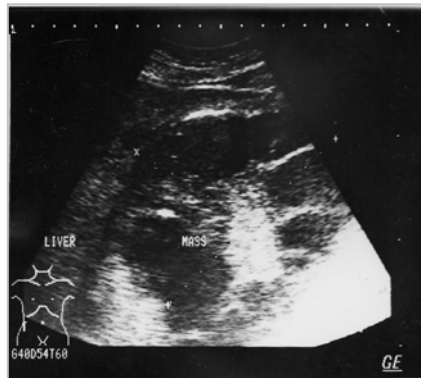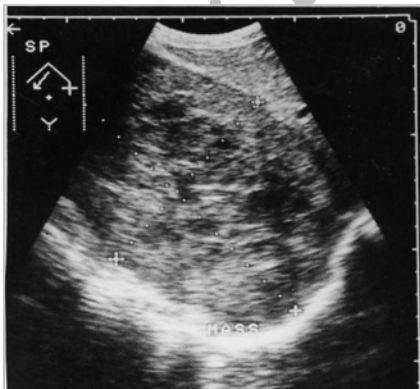
% /

%

% /

% /

% /



Rosset

(% )

(% )

% . (% )

. ( )

. ( )

% -

(% )

Archive of SID

**References:**

- 1- Angulo C., Escribano A.: Hydatid Disease, Biology, Pathology, Imaging and Classification. *Clinical Radiology*, 1998; 53: 863-874.
- 2- Bartos J.L.: Hydatid Disease of the Liver. *Am. J. Surg*, 1988; 135: 597.
- 3- Barki Y., Charuzi Z.: Intrabiliary Rupture of Hydatid Cysts of the Liver. Sonographic diagnosis. *J. Clin. Ultrasound*, 1985; 40: 273-278.
- 4- Bezei M., Jeggi A.: Abdominal Hydatid Disease Us Findings During Medical Treatment. *J. Clin. Ultrasound*, 1998; 12: 175-178.
- 5- Khuro M.S., Zargar S.A.: Echinococcus Granulosus Cysts in the Liver. Management with percutaneous Drainage. *Radiology*, 1997; 180: 147.
- 6- Gadzxijev E.: Complicated Hydatid Cyst of the Liver. Report of A case. *Hepatogastroenterology*, 1995; 42(6): 1008-10.
- 7- Chikhaoui N., Kadiri R.: Complete Evacuation of a Hydatid Cyst of the Liver into the Common Bile Duct. *Ann-Radiol*, 1994; 37(4): 267-9.
- 8- Buligescul L.: 108 Cases of Hepatic Hydatid Cyst. *J. Ultrasound. Med*, 1999; 43(1-2): 93-102.
- 9- Guerran M., Arooyo A.: Hepatic Hydatid Cyst. *Ultrasonography Study*, 1991; 45(3-4): 35-8.
- 10- Banerjee B.: Ultrasound Demonstration of a Leaking Hydatid Cyst of the Liver Causing "Cyst Within a Cyst" Appearance, 1998; 65(775): 604-6.
- 11- Esfahani F., Rooholamini S.A.: Ultrasonography of Hepatic Hydatid Cysts, New Diagnostic Sign. *J. Ultrasound. Med*, 1998; 7: 443.
- 12- Von-Sinner-W.: New Diagnostic Sign in Hydatid Disease, Radiography. Ultrasound, CT and MR Correlated to Pathology. *Clinical Radiology*, 2000; 12(2): 150-2.
- 13- El Hajvan M., Essadki O.: Ultrasound Signs of Pseudoneoplastic Forms of Hepatic Hydatid Cysts. A prospective Analysis of 50 Cases. *Ann. Radiol*, 1998; 39(4-5): 172-81.
- 14- Paksoy M., Karahasanoglu T.: Rupture of the Hydatid Disease of the Liver into the Biliary Tract. *Diage. Surg*, 1998; 15(1): 25-9.
- 15- Zargar S.A., Khuroo M.S.: Intrabiliary Rupture of hepatic Hydatid Cyst. Sonographic and Cholangiographic Appearances. *Gasterointest Radiol*, 1992; 17: 41-5.