




SID



JF-1T20

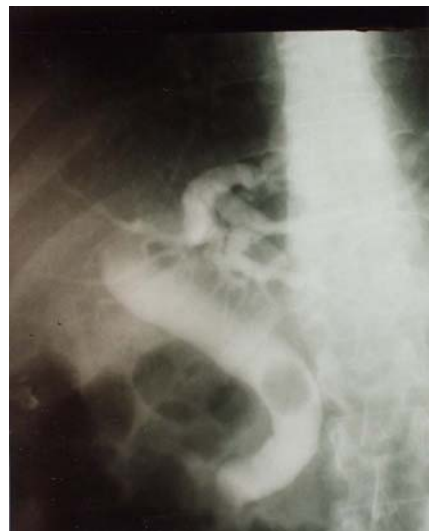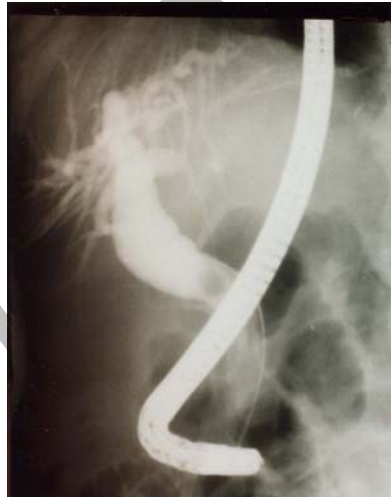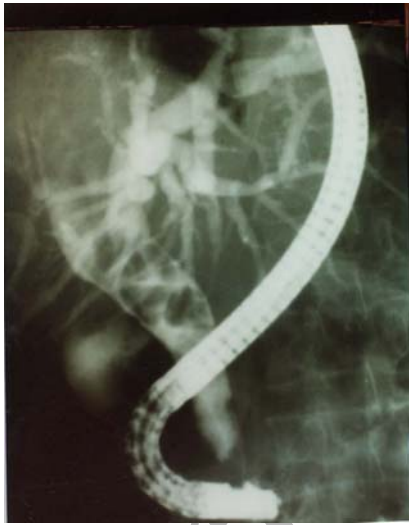FD-34V

Archive of SID

(% / ) / ± / ( )

C

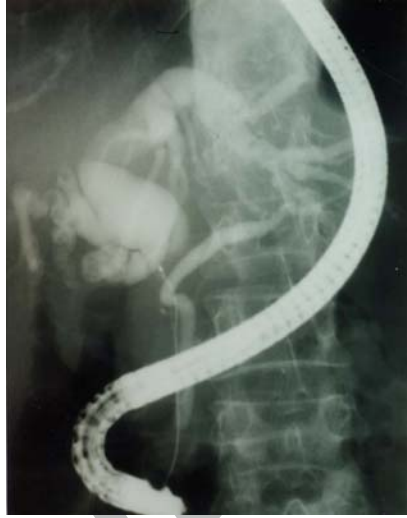(% / )  
(% / ) ( )  
( ) ( )



Archive of

% /

% /



.( )

%

%

)

.(

%

%

%

%

.(

)

				ERCP

% /

ERCP.

% /

.( )

%

% /

<sup>1</sup> Rosch T



%

%

% /

% /

. ( )

% / % /

(EUS)

. ( )

EUS

% %

. ( ) %

)

% %

. (

% %

% %

. ( )

( )

. ( )

%

ERCPC

)

(

II

. ( )

% / %

ERCPC

Archive of SID

ERCP

% % / ERCP

ERCP

ERCP

.( )

**References:**

- 1-[Yeung Y.P., Lo S.F., Yip A.W.](#): Role of ERCP in the management of predicted mild acute biliary pancreatitis. *Asian. J. Surg* 2003; 26(4): 197-201.
- 2-[Lehman G.A.](#): Role of ERCP and other endoscopic modalities in chronic pancreatitis. *Gastrointest Endosc*, 2002; 56(6 Suppl):S237-40.
- 3-[Cwik G., Wallner G., Ciechanski A., Zinkiewicz K., Zgodzinski W., Polkowski W.](#): Endoscopic sphincterotomy in 100 patients scheduled for laparoscopic cholecystectomy:ultrasound evaluation. *Hepatogastroenterology*, 2003 ; 50(53):1225-8.
- 4 [Zhong L., Yao Q.Y., Li L., Xu JR.](#): Imaging diagnosis of pancreato-biliary diseases: a control study. *World J Gastroenterol*, 2003; 9(12): 2824-7.
- 5 Geier A., Gartung C., Dietrich C.G., Lammert F., Wasmuth H.E., Matern S.: Diagnosis of cholestatic disorders. *Med Klin (Munich)*. ,2003; 98(9):499-509.
- 6-[Manfredi R.](#): Diagnostic imaging of the bile ducts and pancreas. *Radiol Med (Torino)*, 2003; 106(3 Suppl 1):104-6.
- 7- [Fiocca F., Santagati A., Ceci V., Donatelli G., Pasqualini M.J., Moretti M.G., Speranza V., Di Giuli M., Minervini S., Sportelli G., Giri S.](#): ERCP and acute pancreatitis. *Eur Rev Med Pharmacol Sci*, 2002.
- 8- [Turner M.A.](#): The role of US and CT in pancreatitis. *Gastrointest. Endosc*, 2002; 56(6Suppl): S241-5.
- 9-[Vitale G.C., Rangnekar N.J., Hewlett S.C.](#): Advanced interventional endoscopy. *Curr. Probl. Surg*, 2002; 39(10): 968-1053.
- 10-Kaw M., Al-Antably Y., Kaw P.: Management of gallstone pancreatitis: cholecystectomy or ERCP and endoscopic sphincterotomy. *Gastrointest. Endosc*, 2002;56(1):61-5.
- 11- [Rosch T., Meining A., Fruhmorgen S., Zillinger C., Schusdziarra V., Hellerhoff K., Classen M., Helmlberger H.](#): A prospective comparison of the diagnostic accuracy of ERCP, MRCP, CT, and EUS in biliary strictures. *Gastrointest Endosc*, 2002;55(7):870-6.
- 12- [Baron T.H., Fleischer D.E.](#): Past, present, and future of endoscopic retrograde cholangiopancreatography: perspectives on the National Institutes of Health consensus conference. *Mayo Clin Proc*, 2002; 77(5): 407-12.
- 13- [Zandrino F., Benzi L., Ferretti M.L., Ferrando R., Reggiani G., Musante F.](#): Multislice CT cholangiography without biliary contrast agent: technique and

initial clinical results in the assessment of patients with biliary obstruction. Eur Radiol, 2002; 12(5):1155-61.

14- [Buffet C.](#): Jaundice. Diagnostic approach Rev Pra, 2002; 52(5): 565-73.

15- Turner M.A.: The role of US and CT in pancreatitis. Gastrointest Endosc, 2002; 56(6 Suppl): S241-5.

16- [Lehman G.A.](#): Role of ERCP and other endoscopic modalities in chronic pancreatitis. Gastrointest Endosc, 2002; 56(6 Suppl):S237-40.

17- [Mark D.H.](#), [Flamm C.R.](#), [Aronson N.](#): Evidence-based assessment of diagnostic modalities for common bile duct stones. Gastrointest Endosc, 2002; 56(6 Suppl):S190-4.

18- Franco E., Deviere J. Endoscopic retrograde cholangiopancreatography. Endoscopy, 2002; 34(11): 882-7.

19- [Tarnasky P.R.](#), [Simmons D.C.](#), [Schwartz A.G.](#), [Macurak R.B.](#), [Edman C.D.](#): Safe delivery of bile duct stones during pregnancy. Am J. Gastroenterol, 2003; 98(9): 2100-1.

20- [Guitron-Cantu A.](#), [Adalid-Martinez R.](#), [Gutierrez-Bermudez J.A.](#), [Aguirre-Diaz A.](#): Endoscopic management of choledocholithiasis during pregnancy Rev Gastroenterol Mex, 2003; 68(1): 11-5.

21- [Rajnakova A.](#), [Goh P.M.](#), [Ngoi S.S.](#), [Lim S.G.](#): ERCP in patients with periampullary diverticulum. Hepatogastroenterology, 2003; 50(51): 625-8.

22- [Napoleon B.](#), [Dumortier J.](#), [Keriven-Souquet O.](#), [Pujol B.](#), [Ponchon T.](#), [Souquet J.C.](#): Do normal findings at

biliary endoscopic ultrasonography obviate the need for endoscopic retrograde cholangiography in patients with suspicion of common bile duct stone? A prospective follow-up study of 238 patients. Endoscopy, 2003;35(5): 411-5.

23- [Ferguson H.R.](#), [Robinson T.J.](#): Treatment options for common bile duct stones. Postgrad Med. J, 2003 ; 79(929):178, 181.

24- [Kraft M.](#), [Lerch M.M.](#): Gallstone pancreatitis: when is endoscopic retrograde cholangiopancreatography truly necessary? Curr. Gastroenterol Rep, 2003; 5(2):125-32.

25- [Fiocca F.](#), [Santagati A.](#), [Ceci V.](#), [Donatelli G.](#), [Pasqualini M.J.](#), [Moretti M.G.](#), [Speranza V.](#), [Di Giuli M.](#), [Minervini S.](#), [Sportelli G.](#), [Giri S.](#): ERCP and acute pancreatitis. Eur. Rev. Med. Pharmacol Sci, 2002; 6(1): 13-7.

26- Jay D Holor & Lyman E. Bilhartz, Gallstone disease and its complications, in Mark Feldman MD, Laurence S Friedman MD , Marvin H Sleisenger MD, Gastrointestinal & Liver Disease ,7<sup>th</sup> ed. vol 1 , Philadelphia Saunders: 2002:1065-90.

27- Albert G., Mulla Jr, MD, MPP, Marc D.: Silverstein, Clinical Decision Analysis, in Thomas C. Chalmers, MD.: Analysis for Clinical Medicine, Manchester, International University Press, 1998:49-64.

A comparison of endoscopic retrograde  
 cholangiopancreatography , ultrasonography and computed tomography  
 in Choledocholithiasis

**Introduction:** Diagnosis of choledocholithiasis (CDL) is very difficult and in some cases it is only possible with laparotomy. On the other hand diagnosis of cholelithiasis is easily made via ultra sonography (US). Endoscopic Retrograde Cholangiopancreatography (ERCP) and computerizing tomography (CT) are also used in CDL diagnosis. In this study the investigators compared the sensitivity and specificity of ERCP, US and CT procedures.

**Material and Methodes:** patients suffering from incomplete obstructive jaundice, biliary colic and cholangitis with or without history of previous cholecystectomy underwent US and CT scan after performing liver function tests, and after bile duct lesion was confirmed ERCP was conducted.

**Results:** A total of 268 cases of ERCP was conducted. Among them 140 (52.2%) patients had either single or multiple common bile duct (CBD) stones. The youngest patient was a 17 year old girl and the oldest one an 85 years old man. The mean age of the patients was 61.7 +/- 19.1 years. US was conducted in all patients and in 23 (16.4%) cases showed the stone exactly, but in 36 (25.7%) cases showed only dilation of intrahepatic bile duct without signs of stone in CBD, this was due to air accumulation in C-loop of the duodenum, also 81 (57.8%) had normal US. If we consider diagnosis of stone in CBD as the gold standard than the sensitivity of US would be 16.4%, but if we consider both dilation of bile duct and presence of stone as diagnostic indications than the sensitivity would rise to 65.5%, at the same time the specificity for US would be 63.3%. CT was done in 12 cases and in 5 showed a mass or tumor which was proven by ERCP to be stone there for giving a sensitivity of 41.6%. In 3 cases CT showed only dilation of intrahepatic ducts without any mass or tumor in CBD, therefore considering both conditions the sensitivity rise to 66.6%. In 4 cases CT showed nothing. The specificity for CT in CBD stoned diagnosis was 28.5%. sensitivity and was calculated 28.5%. Sensitivity and specificity for ERCP in our study were 87.8% and 75% respectively

**Conclusion:** In our study both US and CT had less sensitivity and specificity in comparison with ERCP.

**Keywords:** Choledocholithiasis, ultrasound, computerized tomography, ERCP, Sensitivity, Specificity.