



()

// : // :



Table with multiple rows and columns containing text, percentages, and the acronym 'SRCT'. The text is mostly illegible due to low resolution and blurring.

()

¹SRCT: Small round cell tumors



(SRCT)

SRCT

SRCT .()

(ES/PNET)

/

.()

) ,(DSRCT)

.(

.()

.()

.()

)

SRCT

.(

.()

DAKO

Cg CK LCA NSE

EMA S100 CD20 CD99 DES

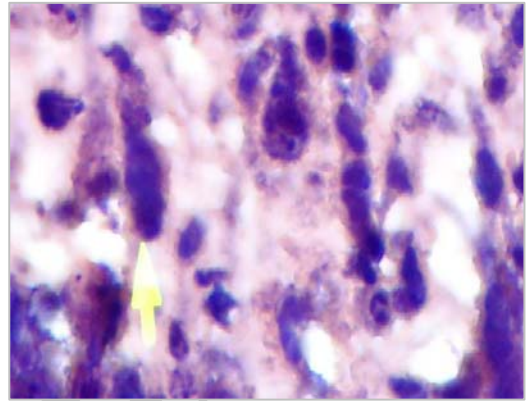
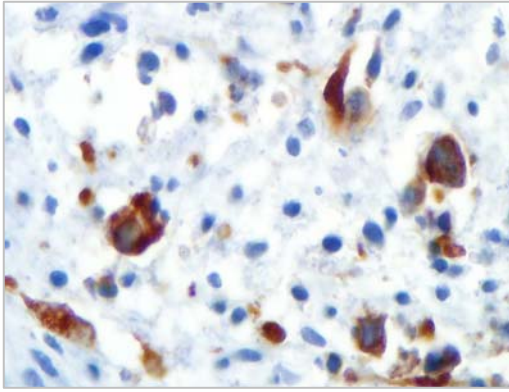
SRCT

-

()

strap

()



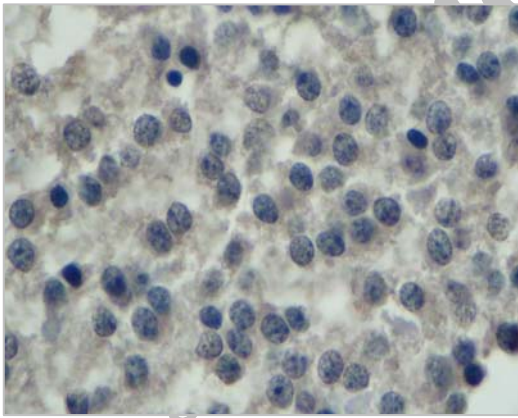
strap

(x

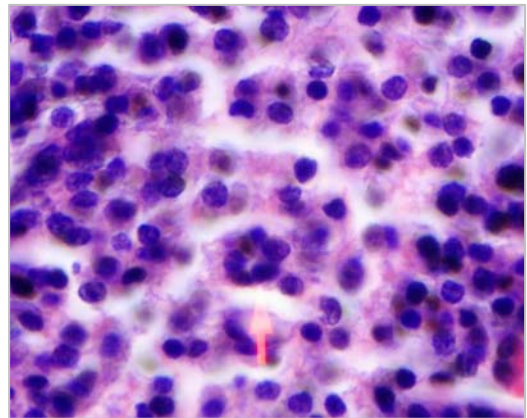
H&E

)

()



NSE



(x

NSE H&E

)

(%)

(%)



(%) .()
(%) ()

(%) ,

(%) .()
SRCT

IHC		
() ES/PNET	ES	SRCT
ES		
		SRCT
		SRCT
		SRCT
ES	ES	SRCT
		SRCT
		SRCT
() ES	ES	SRCT



SRCT

IHC	
	SRCT
ES	SRCT
	SRCT
	SRCT
	SRCT
	SRCT
	SRCT
	SRCT

SRCTs


.()
 PNET ()
 ,() ,() ,()
 ,() ,() ,()
 ,() ,() ,()
 () ,() ,()
 ()
 ()
 (DSRCT)
 ,() ,() ,()
 () ,()
 .()

IHC	
Es	SRCT

SRCTs

... PAS

SRCTs



()

Archive of SID

()

FISH,

RNA DNA

()

IHC

%

(%)

IHC



Archive of SID

SRCT

CD99 NSE

References:

- 1- Devoe K. et al. Immunohistochemistry of small round cell tumors. *Seminars in Diagnostic Pathology* 2000;17:216-224.
- 2- Miettinen M. et al. Soft tissue tumors. in: Damjanov I. et al. *Anderson's pathology*. 10th ed. Mosby; 1996: 2514-15.
- 3- O'sullivan MJ. et al. Visceral primitive peripheral neuroectodermal tumors: a clinicopathologic and molecular study. **Human pathology** 2001; 32(10):1109-1114.
- 4- Miettinen M. et al. Monoclonal antibody NB84 in the differential diagnosis of neuroblastoma and other small round cell tumors. **Am J Surg Pathol** 1998; 22(3):327-332.
- 5- Folpe AL. et al. Immunohistochemistry for analysis of soft tissue tumors. in: Weiss SH.W & Goldman JR. *Enzinger and weiss's Soft tissue tumors*. 4th ed. Mosby; 2001:237.
- 6- Devoe K. et al. Immunohistochemistry of small round cell tumors. *Seminars in Diagnostic Pathology* 2000;17:216-224.
- 7- Miettinen M. et al. Soft tissue tumors. in: Damjanov I. et al. *Anderson's pathology*. 10th ed. Mosby; 1996: 2514-15.
- 8- O'sullivan MJ. et al. Visceral primitive peripheral neuroectodermal tumors: a clinicopathologic and molecular study. **Human pathology** 2001; 32(10):1109-1114.
- 9- Miettinen M. et al. Monoclonal antibody NB84 in the differential diagnosis of neuroblastoma and other small round cell tumors. **Am J Surg Pathol** 1998; 22(3):327-332.
- 10- Folpe AL. et al. Immunohistochemistry for analysis of soft tissue tumors. in: Weiss SH.W & Goldman JR. *Enzinger and weiss's Soft tissue tumors*. 4th ed. Mosby; 2001:237.
- 11- D'Amore ES, Ninfo V. Soft tissue small round cell tumors: morphological parameters. *Semin Diagn Pathol*. 1996 Aug;13(3):184-203.
- 12- Cohn SL. Diagnosis and classification of the small round cell tumors of childhood. **Am J Pathol** 1999;155:11-15.
- 13- Pardo J. de Alava E., Ewing tumor: tumor biology and clinical applications. **Int J Surg Pathol**. 2001 Jan;9(1):7-17.
- 14- D'Amore ES, Ninfo V. Soft tissue small round cell tumors: morphological parameters. *Semin Diagn Pathol*. 1996 Aug;13(3):184-203.
- 15- Cohn SL. Diagnosis and classification of the small round cell tumors of childhood. **Am J Pathol** 1999;155:11-15.
- 16- Pardo J. de Alava E., Ewing tumor: tumor biology and clinical applications. **Int J Surg Pathol**. 2001 Jan;9(1):7-17.
- 17- Hasegawa T, Hirose T, Ayala AG, Ito S, Tomaru U, Matsuno Y, Shimoda T, Hirohashi S." Adult neuroblastoma of the retroperitoneum and abdomen: clinicopathologic distinction from primitive neuroectodermal tumor." *Am J Surg Pathol*. 2001 Jul;25(7):918-24.
- 18- Mirra J.M. et al. *Bone tumors*. 1ST ed. Lea & Febiger; 1989: 326, 577-589, 1088-1117 .
- 19- Altaf FJ, Mansoor I, Jamal AA. Histopathological and immuno-histochemical characteristics of primary renal primitive neuroectodermal tumor. **Saudi Med J**. 2002 Jan;23(1):90-2.
- 20- Deb RA, Desai SB, Amonkar PP, Aiyer PM, Borges AM. Primary primitive neuroectodermal tumour of the parotid gland. **Histopathology** 1999 Sep;35(3):279-80.
- 21- Cenacchi G, Pasquynelli G, Montanaro L, Cerasoli S, Vici M, Bisceglia M, Giangaspero F, Martinelli GN, Derenzini M. Primary endocervical extraosseous Ewing's sarcoma/PNET. **Int J Gynecol Pathol**. 1998 Jan;17(1):83-8.
- 22- Imamura F, Funakoshi T, Nakamura S, Mano M, Kodama K, Horai T. "Primary primitive neuroectodermal tumor of the lung: report of two cases. **Lung Cancer** 2000 Jan;27(1):55-60.
- 23- Movahedi-lankarani S. et al "Primitive neuroectodermal tumors of the pancreas. **Am J Surg Pathol** 2002;26(8):1040-1047.

- 24- Kato k. et al. Ewing sarcoma family of tumor arising in the adrenal gland - possible diagnostic pitfall in pediatric pathology :Histologic,immunohistochemical,ultrastructural and molecular study. **Human pathology** 2001; 32(9): 1012-1016.
- 25- Gemechu T, Ersumo T. Peripheral primitive neuroectodermal tumor presenting in the retroperitoneum: a case report with immunohistochemical study. **Ethiop Med J** 2002 Jan;40(1):69-77.
- 26- Maesawa C. et al. Esophageal extraskletal Ewing's sarcoma. **Hum Pathol** 2002;33(1):130-2.
- 27- Mawrin C, Synowitz HJ, Kirches E, Kutz E, Dietzmann K, Weis S. "Primary primitive neuroectodermal tumor of the spinal cord: case report and review of the literature. **Clin Neurol Neurosurg** 2002 Jan;104(1):36-40.
- 28- Izycka-Swieszewska E, Stefanowicz J, Debiec-Rychter M, Rzepko R, Borowska-Lehman J. Peripheral primitive neuroectodermal tumor within the spinal epidural space. **Neuropathology**. 2001 Sep;21(3):218-21.
- 29- Conran R.M. et al. The pineal, pituitary, parathyroid, thyroid and adrenal glands. in: Stocher J.T. & Dehner L.P. Pediatric pathology 2nd ed. Lippincot Williams and Wilkins; 2001 ,vol 2 ,p 1051-1063.
- 30- Elhajj M, Mazurka J, Daya D. Desmoplastic small round cell tumor presenting in the ovaries: report of a case and review of the literature. **Int J Gynecol Cancer** 2002 Nov-Dec;12(6):760-3.
- 31- Finke NM, Lae ME, Lloyd RV, Gehani SK, Nascimento AG. Sinonasal desmoplastic small round cell tumor: a case report. **Am J Surg Pathol** 2002 Jun;26(6):799-803.
- 32- Mihok NA, Cha I. Desmoplastic small round cell tumor presenting as a neck mass: a case report. **Diagn Cytopathol** 2001 Jul; 25(1):68-72.
- 33- Cummings OW, Ulbright TM, Young RH, Del Tos AP, Fletcher CD, Hull MT. Desmoplastic small round cell tumors of the paratesticular region. A report of six cases. **Am J Surg Pathol**. 1997 Feb; 21(2):219-25.
- 34- Parkash V, Gerald WL, Parma A, Miettinen M, Rosai J. Desmoplastic small round cell tumor of the pleura. **Am J Surg Pathol** 1995 Jun;19(6):659-65.
- 35- Tison V, Cerasoli S, Morigi F, Ladanyi M, Gerald WL, Rosai J. Intracranial desmoplastic small-cell tumor. Report of a case. **Am J Surg Pathol**. 1996 Jan;20(1):112-7.
- 36- Belchis D. Diagnostic immunohistochemistry of pediatric small round cell tumors in: Dabb DJ. Diagnostic immunohistochemistry 1st ed. Churchill livingstone; 2002:517-532.