



|| : || :

EMA

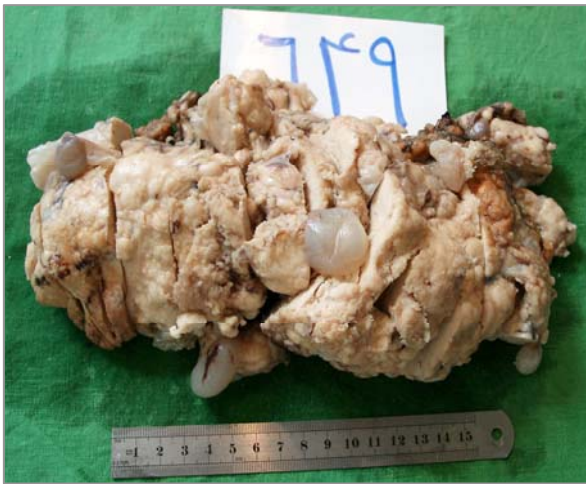
()

.(.)
% .(.)

¹Talerman

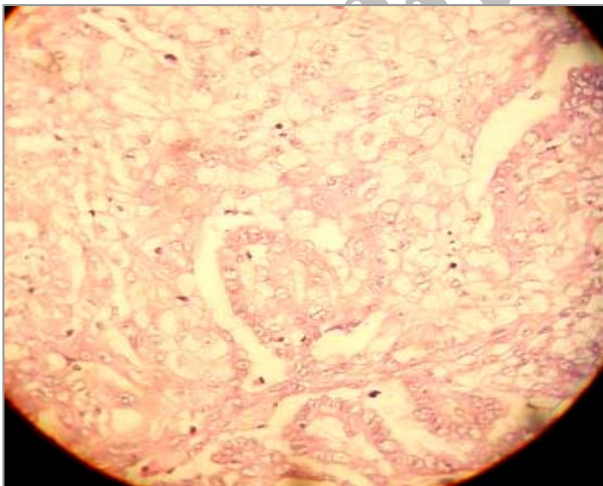
()

()



PAS+

()



X X

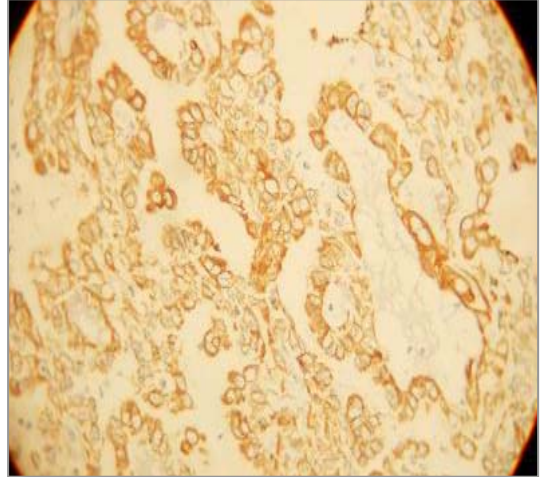
(H/E X)

()



() CEA

EMA ()



(.)

(.)

(.)

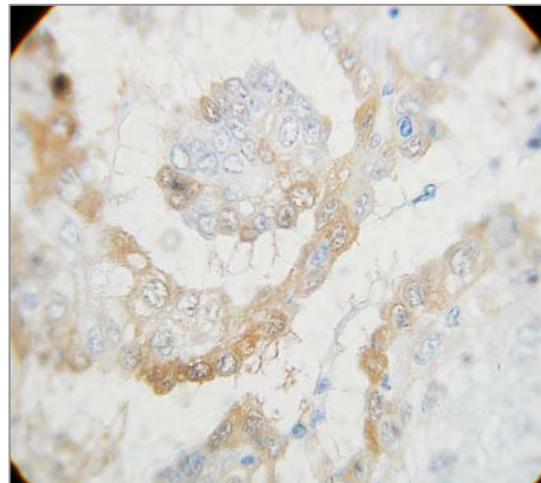
(IHC- X)

(.)

% /

%

()



()

(IHC X)

¹ Adami

² klemperer Rabin

³ Tortorast



.()

.()

()

EMA CEA

.()

BerEP4 B72.3 LUM1

.()

MOC-31

.()

)

/ (

.()

S100

.()

)

(

CD35,CD21

()

.()

HCG

⁴ Talerman

References:

- 1- Weiss SW, Goldblum JR. Mesothelioma. Soft tissue tumors. fourthed. St Louis: Mosby; 2001:1064-1103.
- 2- Rosai J. Respiratory Tract. Surgical pathology: Mosby; 2004:361-363.
- 3- Sternberg S. the pleura. Hecura Battifora. Diagnostic surgical pathology: Lippincot William & Wilkins; 1999:1120-1124.
- 4- Sugarbaker PH, Welchls, Mohamed F, et al. A review of pritoneal mesotheloma at the washington cancer Institue. **Surg Oncol Clin Nam** 2003;12:605-21
- 5- Stocker T. The soft tissue. Coffin C. Pediatric pathology: Lippincott William & Wilkins; 2001:1198- 1199.
- 6- Nascimento AG, Keeny GL, Flecher CD. Deciduoid Peritoneal Mezothelioma. An Unusual Phenotype affecting Young Females. **Am surg pathol** 1994; 48:439-45.
- 7- Suorrcan P, Dgordjeuic J, Colic N, etal . Primary malignant mesothelioma of the peritoneum. **Rom J Gastroenterol** 2003;12:135-7.
- 8- Chung Dj, Kang YW, Kim Bk, et al. Decidaoid Peritoneal Mesothelioma: Ct findings with pathologic correlation. **Abdom Imaging** 2003;28:614-6.
- 9- Sutton D. The small bowel and peritoneal cavity, steve H, text book of radiology and imaging : churchill Livingston; 2003:633.
- 10- Serio G, Scattone A , Pennella A, et al. Malignant deciduoid Mesothelioma of the Pleura: report of two casses. **Histopathology** 2002; 40:348-520.
- 11- ordonez NG. Epithelial mesothelioma with deciduoid features: report of four cases . **Am j surg pathol** 2000; 24:816-23.
- 12- Oros z Nayy p, szentirmay z and etal: Epithelial mesothelioma with decidoid features. **Virehows Archiv** 1999; 434:263-266.
- 13- Reis-Filho JS, Popelz, Milanezif, andetal. Primary epithelial Malignant Mesothelioma of the Pericardium with deciduoid Features: cytohistologic and Immunohistochemical Study 2002;26:117-229-
- 14- Shanks. J H, Harris M, Banerjeess, etal: Mesotheliomas with deciduoid Morphology . **Am. j surg pathol** 2000;24:285-294.
- 15- Shia J, Erlandson R A, Klimstra D . Deciauoid Mesothelioma: a report of 5 cases and literature review. **Ultrastruct pathol** 2002; 26:355-63.
- 16- Okonkwo A, Musunuris, Diazlyr, et al. Deciduoid Mesothelioma : a rare, distinct entity with unusual features. **Ann Diag pathol** 2001;5:168-71.
- 17- Asioli S, Del Piaz G, Damianis, Localised Pleural Malignant Mesothlioma. Repprt of two Cases Simulating Pulmonary Carcinoma and review of the Literature . **Virchows Arch** 2004;445:206-209.
- 18- Kimura N, ogasawara T , Asanum s, et al. Granulocyte-colony Stimulating Factor and interleukin6-producing diffuse deciduoid peritoneal Mesothelioma. **Mod pathol** 2004;13-14.
- 19- Fauci A., et al, Drazen J. Disorder of the respiratory system, Harrisons principles of internal medicin: Mc Graw. Hill; 2001:1474.