



()

/// : // :

SID

HRCT

/ /

:

(TTE)

(TEE)

(TTE)

()

()

-

()

Email: aghileheydari@yahoo.com

()

()



(.)

(.)

II / VI

(

(.)

()

HRCT

%

HRCT

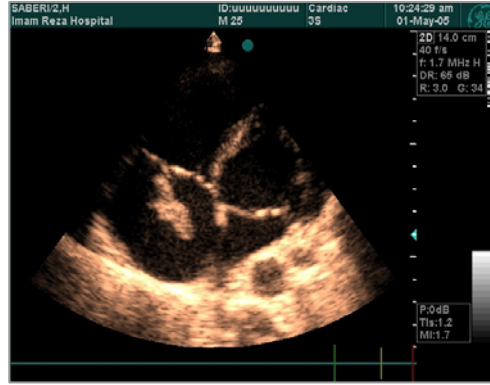
()

()

¹ HRCT: High Resolution Computed Tomography

HRCT

(.)



« »

Archive of SID

%

(.)

% /

(.)

(.)

(.)

%

References:

- 1- Cosson S, Kevorkian JP, Milliez P, Beaufils P, Cohen A. A rare localization in right-sided endocarditis diagnosed by echocardiography: A case report. **Cardiovasc Ultrasound** 2003; 14; 1(1):10.
- 2- Osler W. Gustonian lectures on malignant endocarditis. **Lancet** 1885; 1:415-8.
- 3- Nandakumar, Rajalakshmi MD; Raju, Govinda MD Isolated Tricuspid Valve Endocarditis in Nonaddicted Patients: A Diagnostic Challenge. **Am J Med sci.** 1997; 314(3):207-212.
- 4- Robbins MJ, Frater RWM, Soeiro R, Frishman WH, Strom JA. Influence of vegetation size on clinical outcome of right-sided infective endocarditis. **Am J Med** 1986; 80:165.
- 5- Arnold S, Bayer W, Michael Scheld. Endocarditis and intravascular infections. **In: Mandell GL, Bennett JE, Dolin R; eds. Principles and Practice of Infectious Diseases. 5th ed. New York: Churchill Livingstone; 2000.**
- 6- Takasaki T, Nishida N, Esaki R, Ikeda N. Unexpected death due to right-sided infective endocarditis in a methamphetamine abuser. **Leg Med (Tokyo)** 2003; 5(1): 65-8.
- 7- de Alarcon A, Villanueva JL Endocarditis in parenteral drug addicts. Right-sided endocarditis. Influence of HIV infection. **Rev Esp Cardiol** 1998; 51 Suppl 2:71-8.
- 8- Nalos M, Huang SJ, Ting I, McLean AS. Diagnoses of right-sided empyema complicating tricuspid valve endocarditis during transesophageal echocardiography. **J Am Soc Echocardiogr** 2004; 17(5):464-5.
- 9- Mathew, J, Addai, T, Anand, A, et al. Clinical features, site of involvement, bacteriologic findings, and outcome of infective endocarditis in intravenous drug users. **Arch Intern Med** 1995; 155:1641.