



()

MD

Ph.D


*

// :

// :

SID

Table with multiple columns and rows, containing various symbols and text fragments such as (), %, and :.



()

()

()

()

()

()

	>			<	
%	%	%	%	%	
/	/	/	/	/	
/	/	/	/	/	
	/	/	/		

%

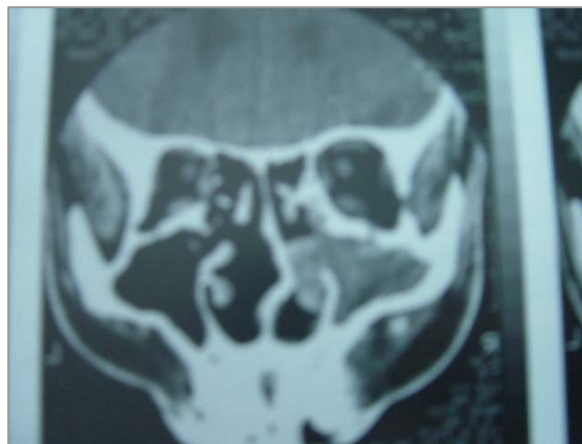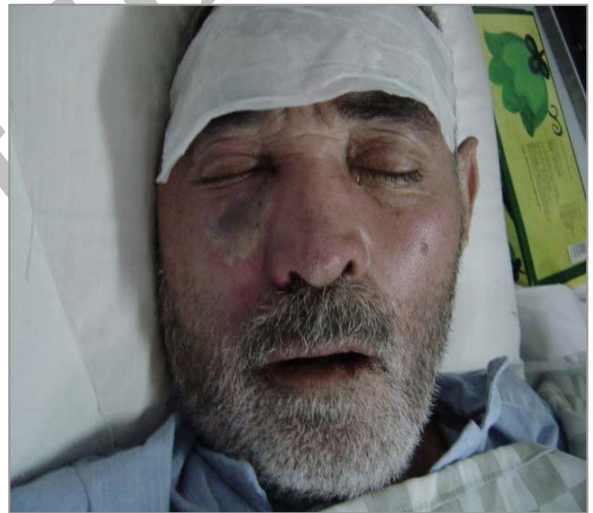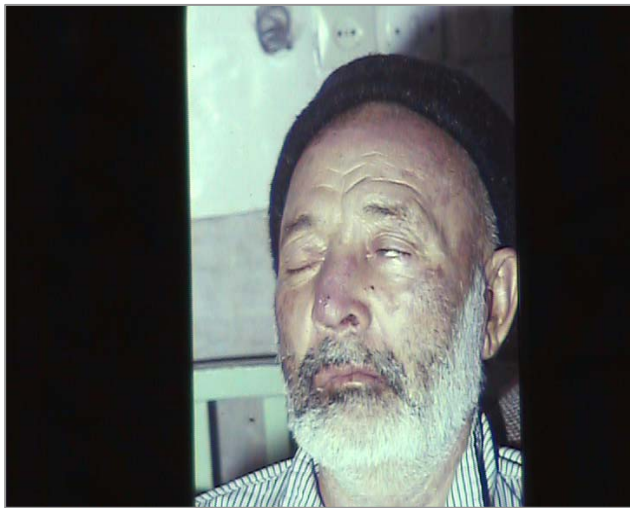
()




()

%	%	%	%	%	%	%
/	/	/	/	/	/	/
/	/	/	/	/	/	/
/	/	/	/	/	/	/

.()





(()

%	%	%	%	%	%
/	/		/	/	/
/	/	/	/	/	/
	/	/	/		/

%

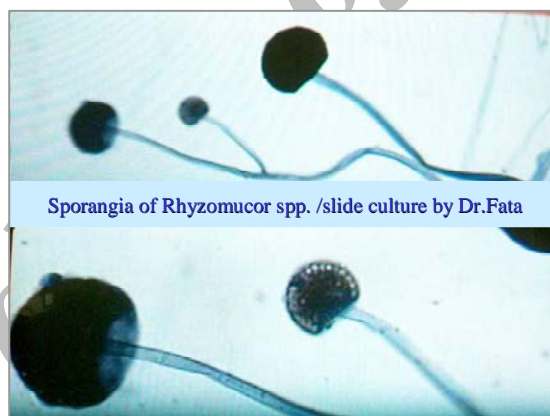
(()

%	%	%	%
/	/		
/	/	/	/
/	/	/	/
/	/	/	/




. % / % / % / ()

(())



()



()

()

()

(, %)

(/ %)

()

()

()

()

()

PH

()

()

()

DKA

()

()

()

()

¹ Diabetic keto acidosis

(B)

(% /)

()

B

%

%

()

Reference:

- 1-Csomor J, Nikolova R, Sinko J. Mucormycosis. **Orv Hetil** 2004; 145(50):2507-13.
- 2- Ibrahim AS, Spellberg B, Avanesian V, et al. Rhizopus oryzae adheres to, is phagocytosed by and damages endothelial cells in vitro. **Infect Immun** 2005; 73(2):778-83.
- 3- Alvarez-Alvarez C, Rodriguez-Conde I, Hortas-Guldris M, San Miguel-Fraile P. Mucormycosis caused by Rhizopus oryzae in a patient with atypical diabetes. **Enferm Infecc Microbiol Clin** 2005; 23(9):576-7.
- 4-Chdi-Chaieb M, Bachir A, et al. Mucormycosis in the diabetic patient. **Presse. Med** 2005; 84(3):218-22.
- 5- Bethge WA, Schmalzing M, Stuhler G, Schumacher U, Krober SM, Horger M, Einsele H, Kanz L, Hebart H. Mucormycoses in patients with hematologic malignancies: an emerging fungal infection. **Haematologica** 2005; 90.
- 6- Spellberg B, Edwards J Jr, Ibrahim A. Novel perspectives on mucormycosis pathophysiology, presentation, and management. **clin Microbio Rev** 2005 ; 8(3):556-69.
- 7- Ali S, Ahmad I. Mucormycosis causing palatal necrosis and orbital apex syndrome. **J coll physicians surg pak**. 2005; 15(3):182-3.
- 8- Bhansali A, Bhadada S, Sharma A, et al. Presentation and outcome of rhino-orbital-cerebral mucormycosis in patients with diabetes, postgrade. **Med J** 2004; 80(949):670-4.

9- Brown J. Zygomycosis. an emerging fungal infection. **Am J Health Syst Pharm.** 2005; 62(24):2593-6.

()

11- Chayakulkeeree M, Ghannoum MA, Perfect JR. Zygomycosis: the re-emerging fungal infection. **Eur J Clin Microbiol Infect Dis** 2006; 28.

12- Munoz del Castillo F, et al. Rhino-cerebral Mucormycosis: differential diagnosis of invasive fungal sinusitis. **An otorrinolaringol Ibero Am** 2004; 31(6):539-48.

13- Trabelsi A, Soua A, Sriha B, et al. Mucormycosis and diabetes three cases reported. **Rev Med liege** 2005 May – June; 60(5-6):545-8

14- Sundaram C, Mahadevan A, Laxmi V, Yasha TC, Santosh V, Murthy JM, Purohit AK, Mohandas S, Shankar SK. Cerebral zygomycosis. **Mycoses.** 2005; 48(6):396-407.

15- Al Soub H, El Deeb Y, Almaslaman IM. zygomycosis in qatar: a retrospective review of six cases. **Allerg Immunol** 2004; 36(10):384-91.

16- Dobrilovic N, wait MA. Pulmonary mucormycosis. **Ann Thoracic surg** 2005; 79(1):354.

17- Peter L, Krola-salmon P, Pignat JC: Rhino-cerebral Mucormycosis. **Rev Neurol** 2005; 161(2):214-7.

18- Pandey A, George J, Raonn. Mucormycosis Causing extensive destruction of maxilla. **Indian J Dent Res** 2004 Apr-Jun; 15(2):74-7.

19- Damante JH, Fleury RN. Oral and rhinoorbital mucormycosis: case report. **J Oral Maxillofac Surg** 1998; 56(2): 267-71[Medline].

()

21- Alfano C, Chiummariello S, Dessy LA, Bistoni G, Scuderi N. Combined mucormycosis and Aspergillosis of the rhinocerebral region. **In Vivo** 2006 Mar-Apr; 20 (2):311-5.

22- Lee EJ, Lee MY, Hung YC. Orbital rhinocerebral mucormycosis associated with diabetic ketoacidosis: report of survival of a 10-year-old boy. **J Formos Med Assoc** 1998; 97(10): 720-3[Medline].

23- Dismukes WE: Introduction to antifungal drugs. **Clin Infect Dis** 2000; 30(4): 653-7.

24- Recovery from rhinocerebral mucormycosis with carotid artery occlusion: a pediatric case and review of the literature. **Pediatr Infect Dis J** 1997; 16(1): 68-71[Medline].

25- Abedi E, Sismanis A, Choi K. Twenty-five years' experience treating cerebro-rhino-orbital mucormycosis. **Laryngoscope** 1984; 94(8): 1060-2[Medline].