

## Endoscopic removal of intravesical calculus around an intrauterine contraceptive device

**Authors:**  
**Dr. Hassan Ahmadnia\***  
Associate Prof. of Urology  
**Dr. Mohamadmehdi Imani**  
Chief resident of Urology

تاریخ ارائه : ۸۴/۲/۱۰ - تاریخ پذیرش : ۸۴/۵/۶

### گزارش درمان اندوسکوپی سنگ تشکیل شده بر روی IUD

#### خلاصه

**مقدمه و هدف :** IUD سال های زیادی مورد استفاده قرار گرفته است و مهاجرت آن از رحم به داخل حفره پریتوئن توسط محققین زیادی گزارش شده است . اگر چه پارگی رحم بوسیله IUD غیرشایع نیست مهاجرت به داخل مثانه و تشکیل ثانویه سنگ عوارض نادری محسوب می شوند. ما یک بیمار ۳۵ ساله را گزارش می کنیم که IUD وی از رحم به مثانه مهاجرت کرده و باعث تشکیل سنگ شده است .

**کلمات کلیدی :** IUD ، جسم خارجی مثانه ، سیستوسکوپی .

**Address corresponding authors:**  
\*Hassan Ahmadnia  
136 Farhang lane, Tehran Street, Mashhad 91366, Iran  
Tel: 0098-511-8595880  
Fax: 0098-511-8417404  
E-mail: ahmadnia2001@yahoo.com

### **Introduction:**

We report a 35 year old woman with intravesical calculus around intrauterine contraceptive device. We describe a technique of stone and IUD removal using a percutaneous nephrolithotomy sheath and forceps.

### **Case report:**

In 1997, a 35 year old woman with 5 children had an intrauterine contraceptive device (IUD) inserted in the uterus by a paramedic. Three months after insertion she attended the emergency room because of lower abdominal pain and bleeding from the vagina, and an attempt to remove the IUD was unsuccessful. She was lost to further follow-up and any definitive management. In 2002, when she had already had an abortion, she presented with urethral pain during micturition, dysuria, dyspareunia and increased frequency and nocturia. A plain film and ultrasonogram of the pelvis revealed that she had a T-shaped radio-opaque shadow in the pelvis, that the device had perforated the uterus and migrated to the bladder (Fig 1).

Cystoscopy under general anesthesia confirmed a large bladder stone that was fixed in the bladder wall (Fig 2). We used a 26F nephroscope instead of cystoscope. The first, arms of IUD were grasped outside of bladder wall. Then, by using of Swiss Lithoclast, bladder stone around IUD fragmented. Therefore, both IUD and the fragments of stone were removed completely (Fig 3). An indwelling urethral catheter was left overnight and the patient discharged within 24h of the procedure.

### **Discussion:**

The IUD has been in use for many years and transmigration of the device from uterine to the pelvic cavity (bladder, ureter and sigmoid colon) has been reported (1, 2, 3). This case showed that uterine perforation can occur when the device is inserted, and similar cases of an intravesical IUD, were reported by Eckford et al (4) and Maskey et al (1).

Various objects have been removed from the lower urinary tract. Open surgery is often necessary, although endoscopic extraction of foreign bodies is possible and should be attempted before resorting to cystostomy (5). In our case, endoscopic removal

intravesical stone around the IUD was performed successfully. In conclusion, we believe that endoscopic removal of foreign body may be helpful, and it should be tried before resorting to open surgery.

A large number of cases are reported in which various types of foreign bodies migrated into the bladder by an ulcerative process from different organs adjacent to the bladder. These objects include chicken and fish bones, pins and needles, a pencil, a thermometer, a swallowed bullet, toothpicks, a broom bristle and the whalebone mouthpiece of tobacco pipe. All perforated the bladder via the gastrointestinal tract. An intravesical bunch of hair from a perforating dermoid cyst of the ovary and skeletal remnants from extrauterine pregnancies have also been reported. Other foreign objects of the bladder that perforated via the vagina mostly as result of masturbation injuries were a cucumber, a hairpin and a wooden shoe tree. If the intestine is adherent to the bladder due to an inflammatory or neoplastic process, communication via an intestinovesical fistula may develop between the 2 compartments and a foreign body may migrate into the bladder (6).

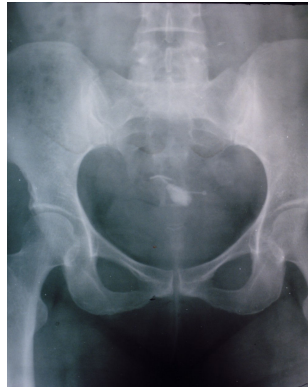## Abstract

**Introduction and Objective:** The intrauterine contraceptive device has been in use for many years, and migration of the device from the uterus to the pelvic cavity has been reported by many investigators. Although perforation of the uterus by an intrauterine contraceptive device is not uncommon, intravesical migration and secondary stone formation are rare complications. We report on a 35 years old woman in whom an intrauterine contraceptive device migrated from the uterus to the bladder and resulted in formation of a stone.

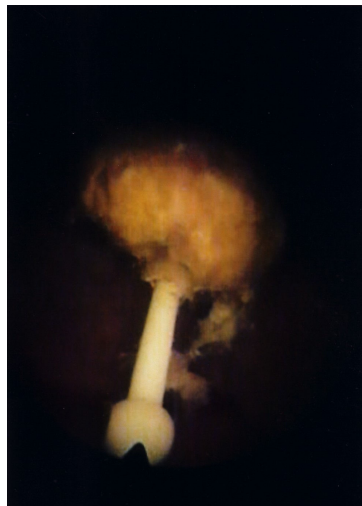**Key Words:** IUD , Vesical foreign bodies , Cystolithotripsy.

## References:


- 1- Maskey CP,Rahman M,Sigdar TK, et al. R:Vesical calculus around an intra-uterine contraceptive device. Br J Urol 1997; 79:654-655.
- 2- Evans JW,Chapple CR,Ralph DJ, et al. Bladder calculus formation as a complication of the stamey procedure. Br J Urol 1990; 65:580-2.
- 3- Qublan HS,Dabbas MA.Misplacement of an intrauterine contraceptive device into the ureter after uterin wall perforation . Br J Urol 2002; 90:135-136.
- 4- Eckford SD,Persad RA,Brewster SF,et al. Intravesical foreign bodies: five year review. Br J Urol 1992; 69:41-5.
- 5- Chitale SV,Burgess NA.Endoscopic removal of a complex foreign body from the bladder. Br J Urol 1998; 81:756-757.
- 6- van Ophoven A, deKernion JB:Clinical management of foreign bodies of the genitourinary tract. J Urol 2000 Aug; 164(2):274-87.



**Fig 1- Plain film of the pelvis showing the encrusted IUD**



**Fig 2- Endoscopic appearance bladder stone around IUD. An arm of the IUD was seen.**



**Fig 3- IUD and bladder stone around of it after removal from bladder**