



(¹)Ackerman

()

/

NHB

()

NHP

/

/

/

NHP

I

:

NHP

;

;

;

;

;

;()

(¹)Moorrees

NHP

(¹)Bjern

(¹)Grainger Popvich

;()

NHP

(¹)Lebert Moorrees

mesh

(¹)Durer

(¹)Thompson, Popovich

)

(¹)Jacobson

(



Asahi

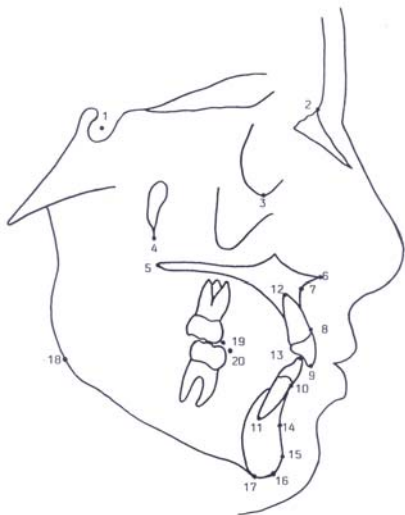
kvp

x

x

kvp

- (A) PTM (Or) (Na) (S)
- (IS1) (ANS) (PNS)
- (AP1) (Pr)
- (Ii) ((Id)
- (Gn) (AP1) (B)
- (Pog) (Me)
- (Go) (UMC)
- (LMC)



() Showfety



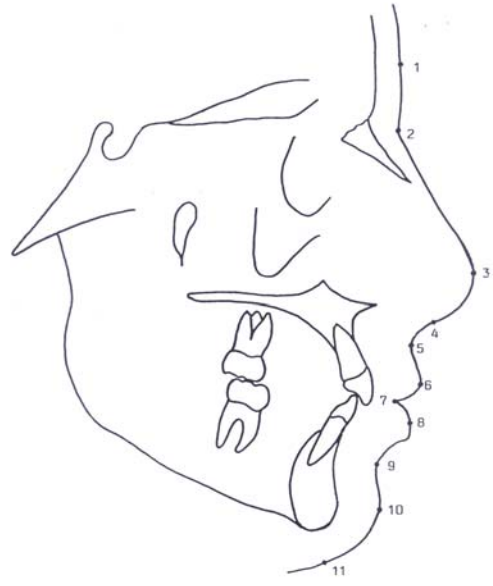(G) :()

(Sn) (P) (Na')

(LS) (SLS)

(ILS) (Li) (Sto)

(Me') (Pog')



NHP

X

Y

()

Archive of

(x,y)

Y X

y ,x

x

()

+

+ +

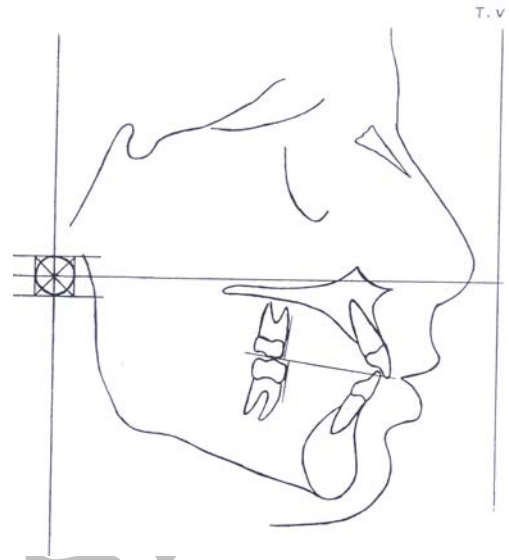
()

()



()

SPSS



T-test

T-test/pair

T-test

t-test

X=- Y=-	X=+ Y=+
X=- Y=-	X=+ Y=-

Archive of S

()

()

()

x

y

y

x

()



Moyers, .

()Johnston. Harris

Bo.Na

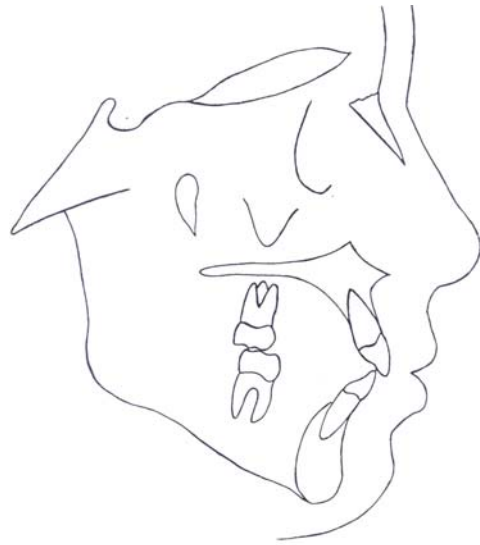S

S1

Bo-Na

S1- Na Bo- S1

Bo-Na



Bo- Na

S1.

NHP

()

()

()Liebgott .

x

PNS

y

()Ackerman

NHP

N

SN

x

()

()

y

N



Go Y

() Harris Moyers , Johnston .

Archive of SID

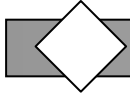
() Ackerman .

T-test


./.

x,y

X



1. Bjern R. A comparison between the Frankfort horizontal and the sella-nasion line as reference planes in cephalometric analysis. *Acta Odontol Scand* 1957; 15:1-12.
2. Moorrees CFA, Kean MR. A basic consideration in the interpretation of cephalometric radiographs. *Am J Phys Anthropol* 1958; 16:213-34.
3. Popovich F, Grainger R. *Orthodontic in mid-century*. 1st ed. St. Louis: Mosby ; 1958. p. 85.
4. Moorrees CFA, Lebert L. Mesh diagram and cephalometrics. *Angle Orthod* 1962; 32:214-31.
5. Popovich F, Thompson GW. Craniofacial templates for orthodontic case analysis. *Am J Orthod* 1977; 71:406-20.
6. Jacobson A. The proportionate template as a diagnostic aid. *Am J Orthod* 1979; 75: 159-72.
7. Ackerman RJ. The Michigan School study cephalometric norms expressed in template form. *Am J Orthod* 1979; 75:282-90.
8. .
9. .
10. Showfety K, Peter S, Vig Steven Matteson Cieb Philips. Associations between the postural orientation of sella-nasion and sheletodental morphology. *Angle Orthod* 1987; 57: 99-112.
11. Showfety KJ. A simple method for taking natural head position cephalograms. *Am J Orthod* 1983; 83:495-500.
12. Jacobson A. *Radiographic cephalometry from basis to videoimaging*. 1st ed. Chicago: Quintessence; 1995. p. 127.
13. Lundstrom A, Forsberg CM, Peck S, Mc William J. A proportional analysis of the soft tissuefacial profile in young adults with normal occlusion. *Angle Orthod* 1992; 62: 127-32.
14. Proffit WR, Fields HW. *Contemporary orthodontics*. 2nd ed. St. Louis: Mosby; 1993. p. 160.
15. Proffit WR, White RP. *Surgical orthodontic treatment*. 2nd ed. St. Louis: Mosby; 1990. p. 116.
16. Liebgott B. Cephalometric analysis by using a template. *Angle Orthod* 1978; 48: 194-201.
17. Harris JE, Johnston L, Moyers RE. Cephalometric template: Its construction and clinical significance. *Am J Orthod* 1963; 44: 249-63.
18. .
19. Proffit WR, Fields HW. *Contemporary orthodontics*. 3rd ed. St. Louis: Mosby; 2000. p. 148.



Cephalometric template for children aged 11-13 with
normal occlusion in Mashhad

Basafa M.* D.D.S. Associate Professor, Department
of Orthodontics, School of Dentistry, Mashhad
University of Medical Sciences, Iran

Khanemasjedi M. D.D.S. Assistant Professor,
Department of Orthodontics, School of Dentistry,
Ahvaz University of Medical Sciences, Iran

Abstract

Introduction

The aim of this study, which has been done for the first time in Mashhad, was to prepare lateral cephalometric templates for boys and girls with normal in Mashhad and use of them for diagnosing and treatment planning of malocclusions in patients.

Materials and Methods

In this study 29 girls and 25 boys, aged 11 to 13, were chosen from schools of Mashhad. After preparing files and taking impressions, their lateral cephalograms were taken in NHP and the template preparation process with a new technique was carried out and the templates were extracted.

Results

4 templates were extracted: 2 for girls aged 11 and 12, and 2 for boys aged 12 and 13.

Conclusion

Using template is a very fast and reliable way for diagnosing and treatment planning in orthodontics. The templates of this study can be used for patients of the above-mentioned age group.

Key words: Cephalometry, NHP, template.

*Corresponding Author