



تاریخ دریافت ۸۳/۱۱/۲۸، تاریخ پذیرش ۸۴/۰۴/۱۵

()

(.)

(.)

()

()

³ One Bone Forearm Reconstruction

⁴ Hey Groves

⁵ Green Wood

⁶ Ulnar Dysmelia

.()

Jamar

Pinch Grip Power Grip

() C

.()

.()

) II

.() (

%

Lazy S

()

.()

Wedge

«

»

.()

.()

Pinch Power Grip

Grip

.()

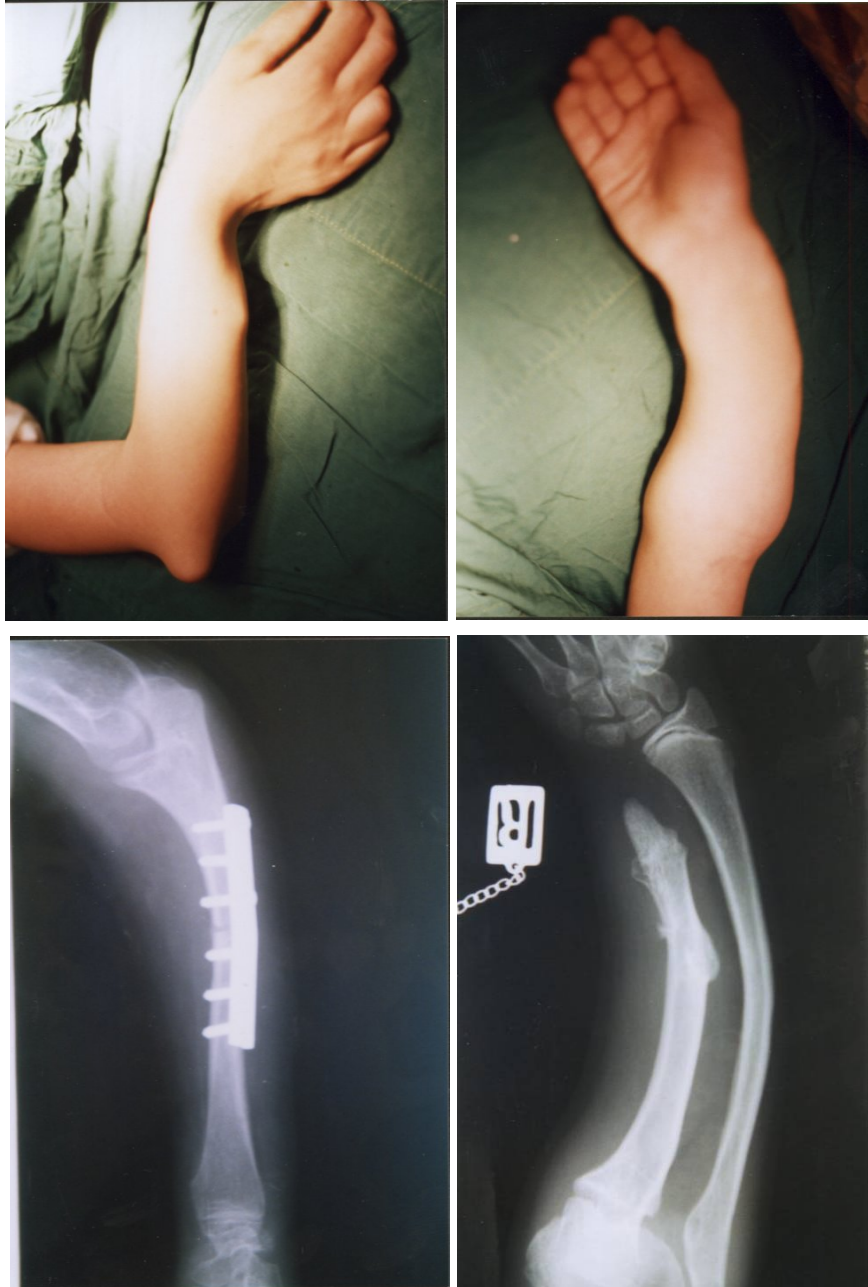
()

³ Ulnar Club Hand
⁴ Vitale

¹ Kummel
² Ogden

(.)

(.)



References:

1. Allende C, Allende BT Post- Traumatic One Bone Forearm Reconstruction. *J Bone Joint*, 2004, 86- A (2): 364, 369.
2. Castle ME. One Bone Forearm. *J Bone Joint surg*, 1974, 56-A (6): 1223-1227.
3. Kitano K, Tada K. One Bone Forearm for partial Defect of the Ulna. *J pediater orthop*, 1975, 5 (3): 290- 293.
4. Rodgers WB, Hall JE. One Bone Forearm as a Salvage procedure for Recalcitrant Forearm Deformity in Hereditary Multiple Exostosis. *J Pediatr Orthop*, 1993, 13 (5); 587- 591.
5. Ogden JA, Watson HK, Bohne W. Ulna Dysmelia. *Bone Joint Surg*, 1976, 58-A (4): 467- 475.
6. Tonkin MA: Ulna Longitudinal Deficiency. In Green D, Hotchkiss RN, Pederson WC, (eds), *Green's operative Hand Surgery*. Pennsylvania, Churchill Livingstone, 358-368.
7. Mccarrol HR. Congenital Anomalies, A 25-years Overview. *J Hand Surg*, 2000, 25-A (6): 1007- 1032.
8. Peterson CA, Maki S, Wood MB. Clinical Results of the One Bone Forearm. *J Hand Surg*, 1995, 20- A (4): 609- 618.